

Results of Needle Aponeurotomy for Dupuytren Contracture in Over 1,000 Fingers

Gary M. Pess, MD, Rebecca M. Pess, BA, Rachel A. Pess, BA

Purpose To critically review the efficacy, recurrence rate, and complications of needle aponeurotomy (NA) for the treatment of Dupuytren contracture.

Methods This was a retrospective study of the results of NA for the treatment of Dupuytren contracture. We included in the study all patients who had NA performed for metacarpophalangeal (MP) or proximal interphalangeal (PIP) joint contracture of 20° or greater between March 2005 and May 2008. There were 474 patients with 1,013 fingers treated. The average age was 62 years (range, 33–92 y). Pre-procedure MP joint contracture averaged 35° (range, 15° to 95°), and PIP joint 50° (range, 15° to 110°). Immediately postprocedure and at least 3 years after treatment (range, 3.0–6.2 y), we measured MP and PIP joint contractures and reviewed records for complications.

Results MP joint contractures were corrected an average of 99% and PIP contractures an average of 89% immediately postprocedure. At final follow-up, 72% of the correction was maintained for MP joints and 31% for PIP joints. The difference between the final corrections for MP versus PIP joints was statistically significant. When we compared the final results of patients age 55 years and older versus under 55 years, we found a statistically significant difference at both MP and PIP joints, with greater correction maintained in the older group. Gender differences were not statistically significant. Needle aponeurotomy provided successful correction to 5° or less contracture immediately postprocedure in 98% (791) of MP joints and 67% (350) of PIP joints. There was recurrence of 20° or less over the original postprocedure corrected level in 80% (646) of MP joints and 35% (183) of PIP joints. Complications were rare except for skin tears, which occurred in 3.4% (34) of digits.

Conclusions This study shows that NA is a safe procedure that can be performed in an outpatient setting. The complication rate was low, but recurrences were frequent in younger patients and for PIP contractures. (*J Hand Surg* 2012;37A:651–656. Copyright © 2012 by the American Society for Surgery of the Hand. All rights reserved.)

Type of study/level of evidence Therapeutic IV.

Key words Dupuytren contracture, fasciotomy, needle aponeurotomy, recurrence, needle fasciotomy.

From Central Jersey Hand Surgery, Eatontown, NJ; the Department of Orthopedic Surgery, Drexel University School of Medicine, Philadelphia, PA; the Steinhardt Department of Physical Therapy, New York University, New York, NY; and the Nathan Weiss School of Graduate Studies, Kean University, Union, NJ.

The authors acknowledge the assistance and dedication of the entire staff of Central Jersey Hand Surgery; Central Jersey Surgery Center; Physicians' SurgiCenter; Metropolitan Surgical Institute; Community Medical Center; and Kimball Hospital; Matthew Pess, BS; and Carolyn Cyrway, MOT, CHT. Dr. Pess expresses appreciation to Dr. Lermusiaux and

colleagues at Unité Rhumatologique des Affections de la Main at Hôpital Lariboisière in Paris for teaching him needle aponeurotomy and for their kindness and hospitality.

Received for publication September 22, 2011; accepted in revised form January 19, 2012.

G.M.P. is a speaker for Auxilium Pharmaceuticals, Inc.

Corresponding author: Gary M. Pess, MD, Central Jersey Hand Surgery, 2 Industrial Way West, Eatontown, NJ 07724; e-mail: handman613@gmail.com.

0363-5023/12/37A04-0002\$36.00/0
doi:10.1016/j.jhssa.2012.01.029

DUPUYTREN DISEASE IS a benign fibromatosis of the fascia of the hand and fingers. Henry Cline¹ proposed treatment in 1777. He used a blade to section the contracted cords, performing a fasciotomy or aponeurotomy. In 1822, Cooper² performed a percutaneous fasciotomy using a pointed bistoury to divide the pathological cords. Percutaneous procedures were commonly used throughout the 1800s and were documented by Adams³ in 1892. Open excision of the abnormal fascia became the standard treatment after the introduction of general anesthesia in the mid-1800s. Goyrand⁴ performed a limited fasciectomy, and Ferguson⁵ proposed treatment by open excision of the diseased fascia.

In 1959, Luck⁶ reintroduced subcutaneous fasciotomy for the involitional and residual stages of Dupuytren disease. Using a fasciatome, he sectioned the fibrous cords subcutaneously at multiple levels in the palm. For the involitional stage, he also recommended open resection of the palmar nodules.

In 1972, Lermusiaux and Debeyre⁷ described using a needle, rather than a knife, to divide the cords. Needle fasciotomy was less invasive than open fasciectomy, and patients had a quicker recovery of function. Badois et al⁸ (1993), Foucher et al⁹ (2003), and van Rijssen and Werker¹⁰ (2006) reported on the use of fasciotomy, and its acceptance has increased.

In this article, we present the results of a retrospective study on the use of NA in adults with Dupuytren disease. We undertook a critical review of the efficacy, recurrence rate, and complications after a minimum follow-up of 3 years postprocedure.

MATERIALS AND METHODS

We included in the study all patients who had NA performed between March 2005 and May 2008 for a flexion contracture of 20° or greater of the metacarpophalangeal (MP) or proximal interphalangeal (PIP) joint. We included contractures between 15° and 19° only if they were treated at the same time as a coincident contracture in the same finger or same hand of 20° or greater. We treated contractures of 15° or less at the same time, if present, but did not include the results in the study. There was no exclusion of patients who had PIP contractures 90° or greater. All patients with Dupuytren contracture and a palpable cord were treated with NA. We did not offer NA if the contracture resulted from postsurgical scarring or inadequate skin. Patients were required to sign consent and fill out a questionnaire before the procedure. Immediately postprocedure, we recorded insertion points used and the resultant correction achieved. All measurements of the

TABLE 1. Digit and Joint Treated

	%	N
Digit		
Thumb	1	9
Index	5	52
Middle	19	188
Ring	36	363
Little	40	401
Joint		
MP	61	807
PIP	39	522

MP and PIP joints were of passive motion taken with a goniometer placed dorsally while the wrist and carpo-metacarpal joints were maintained in neutral positions.

We asked patients to return for a follow-up visit 2 to 6 weeks postprocedure. If they could not return for their examination, they were asked to give an e-mail follow-up to assess postprocedure complications. After a minimum of 3 years, we reexamined patients' fingers, obtained joint measurements, questioned patients about complications, and reviewed all patients' records. Measurements of residual contracture and recurrence were obtained by reexamination by the senior author (85%), the patient's local physician (< 1%), a hand therapist (9%), or the patient, using a protractor (6%). Patients performing their own measurements received specific instructions on how to perform the measurement and were not included in the study if they could not adequately complete the task.

The Institutional Review Board of Community Medical Center approved this study. There were 474 patients with 1,013 fingers treated; 78% (370) of patients were men. The average age was 62 years (range, 33–92 y). There was a preponderance of ulnar-sided digits, with 40% little and 36% ring (Table 1). Preprocedure contracture at MP joints averaged 35° (range, 15° to 95°; SD 19), and at PIP joints averaged 50° (range, 15° to 110°; SD 22). Four patients were deceased and lost to follow-up. We obtained final follow-up in 91% (431) of patients treated. The minimum follow-up was 3 years, with a range of 3.0 to 6.2 years.

We calculated percent correction by individually matching the preoperative data with the postoperative data for the same joint and then averaging the individual percent corrections. We performed statistical analysis using independent *t*-tests. Final results were analyzed for joint treated, digit, gender, and age at time of the NA procedure.

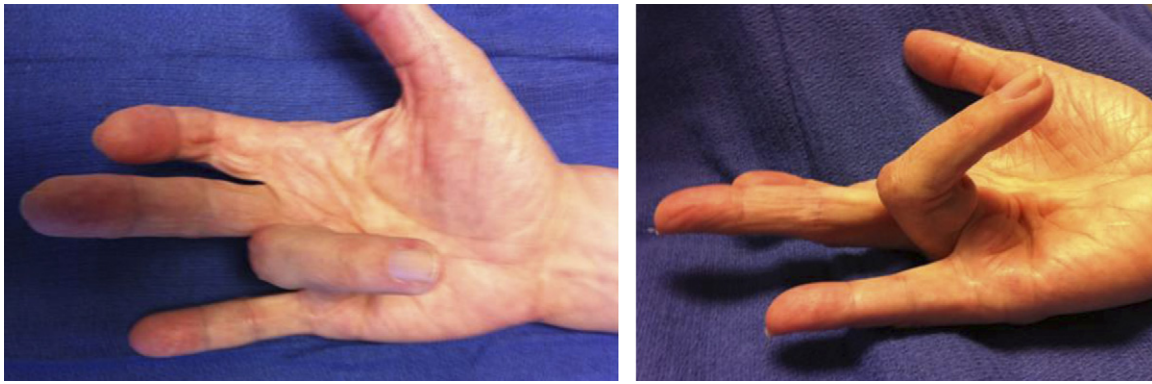


FIGURE 1: Preprocedure photographs of hand with Dupuytren contracture affecting the index PIP joint and ring finger MP and PIP joints. Patient is attempting full active extension of fingers.

To determine efficacy, we evaluated several criteria: percent correction of contracture, correction of the contracture to 5° or less immediately after 1 procedure, recurrence of contracture of less than 20° over the original postprocedure corrected level, and maintenance of improvement of extension 50% or more of the initial contracture at final follow-up.

Operative technique

We performed needle aponeurotomy in an outpatient treatment room with the patient recumbent under local anesthesia. In some patients (by their choice and not based on the severity), light sedation was used in a surgery center, with the anesthesiologist making sure that the patient remained responsive to stimuli. The patient's hand was prepped with antiseptic solution. We placed a stack of folded towels under the hand to aid in extension of the MP and PIP joints. We carefully chose portal sites between skin creases in areas of definite cords and marked them with a surgical marker.

We performed intradermal anesthesia in patients with a high level of anxiety, with less than 1 mL lidocaine 1% plain in the palmar portals, before releasing any cords. Only the dermis was penetrated and injection was performed as the needle was withdrawn. This syringe was placed aside.

We filled a 5-mL syringe with 3 mL lidocaine 1% plain and 1 mL methylprednisolone acetate injectable suspension 40 mg (Depo-Medrol; Pharmacia and Upjohn Co., New York, NY). We did not use corticosteroids for patients with diabetes mellitus. Short 25-gauge, 16-mm (5/8-in)-length needles were used exclusively. We did not apply a tourniquet. Patients had been asked to stop anticoagulation, if possible, but blood thinners were not considered a contraindication to the procedure.

Each time we entered a portal, we injected 0.1 mL of the lidocaine/corticosteroid mix into the local area and used the needle as a scalpel to release the cord at multiple levels from proximal to distal. The cord was palpated and then pinched between the fingertips. The needle was aligned perpendicular to the cord. The finger was flexed and extended after needle insertion to confirm that the needle was not within the flexor tendon. We made insertion portals at the areas of maximum bowstring over a palpable cord. We selected areas farthest from the neurovascular bundle and constantly asked patients if they felt any electric shocks. Portals were spaced 5 mm apart and were not made in skin creases.¹¹ We did not use Doppler or ultrasound.

We used 3 maneuvers: perforate, slice, and clear. We performed an up-and-down perforation of the cord with the needle oriented vertically, and a gentle side-to-side slicing motion with the needle tip perpendicular to the cord's longitudinal axis. In areas of pitting, we employed a tangential clearing motion to separate the cord and nodule from the dermis. This helped lower the incidence of skin tears. We placed gentle extension tension on the cord during the release and then used passive extension to rupture the cords. The needle was changed frequently to maintain sharpness. We noted a crackly feeling as the fibers were released.

After completing the release distally, we reassessed the palm and finger for residual cords. We released each residual cord, again in a proximal to distal direction. In patients with severe PIP joint contractures, we used a nerve block or PIP joint injection with lidocaine 1% plain for supplementary anesthesia. This was performed after NA was completed to help reduce pain during the extension procedure. After we were satisfied that all possible cords had been released, we injected nodules with the mixture of lidocaine and corticosteroid (Figs. 1–3).

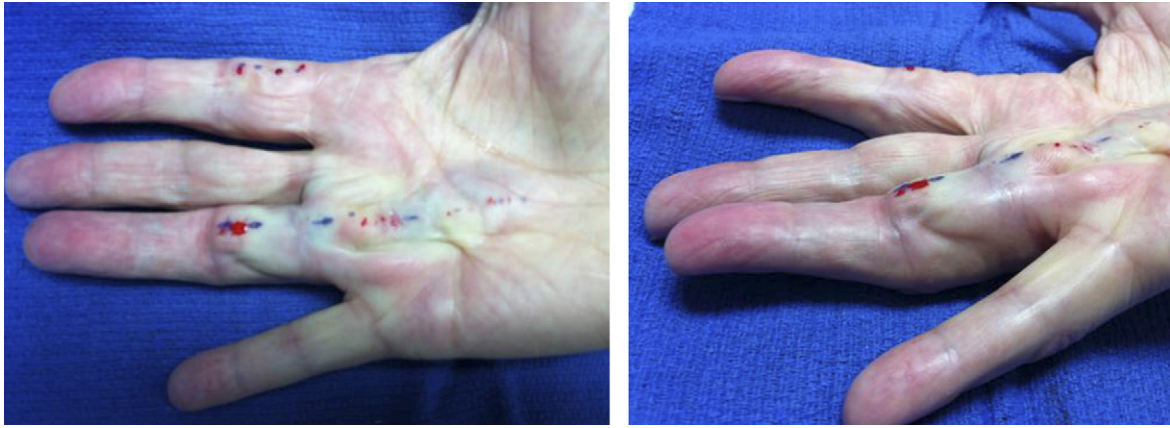


FIGURE 2: After needle aponeurotomy photographs of hand: index and ring fingers released.

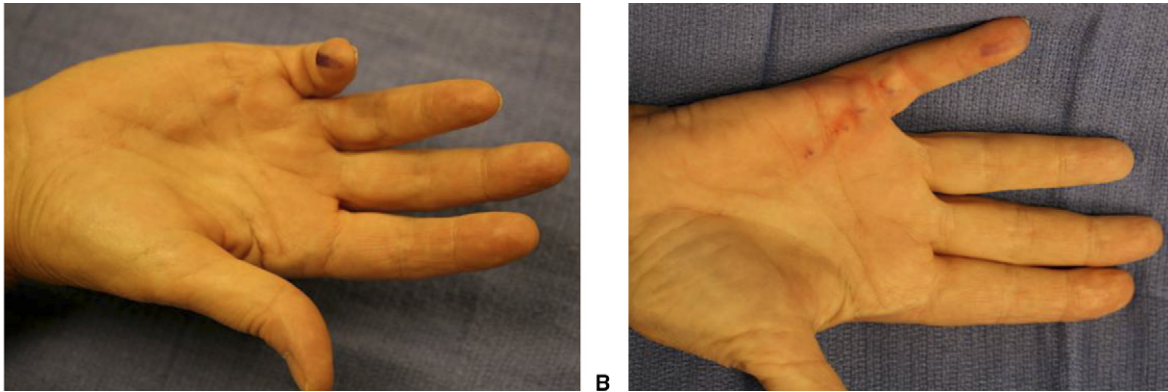


FIGURE 3: A Preprocedure photograph of a severe Dupuytren contracture of the little finger MP and PIP joints. Patient is attempting full active extension of the finger. **B** Immediately after NA: little finger contractures released.

We applied a light dressing with gauze bandage and allowed removal of the bandage that evening. The senior author fitted a fiberglass or aluminum splint immediately postprocedure and recommended night use for 4 months. Patients were instructed to exercise at home a minimum of 10 minutes twice a day for 4 weeks. Written instructions included active flexion and extension range of motion exercises and gentle passive extension stretching. Heavy grasping was not advised for the first 2 weeks.

RESULTS

There was immediate correction of MP joint contractures from an average of 35° preoperatively (range, 15° to 95°; SD 19) to an average of 1° postprocedure (range, 0° to 80°; SD 4). At final follow-up, there was a residual contracture of 11° (range, 0° to 80°; SD 18). Metacarpophalangeal joint contractures were corrected an average of 99% immediately postprocedure and maintained an average correction of 72% at long-term follow-up.

For PIP joints, NA immediately reduced the contracture from 50° preoperatively (range, 15° to 110°; SD

22) to 6° postprocedure (range, 0° to 87°; SD 11). At the time of final follow-up, the contracture had recurred to an average of 35° (range, 0° to 95°; SD 25). Proximal interphalangeal joint contractures were corrected an average of 89% immediately postprocedure and maintained an average correction of 31% at final follow-up. The difference between the final corrections for MP versus PIP joints was statistically significant ($P < .001$). Results were similar for middle, ring, and little MP and PIP joints (Table 2).

Patients age 55 and older had mean final corrections of 74% at the MP joint and 34% at the PIP joint, while those under 55 had mean corrections of 65% and 21%, respectively. There was a statistically significant difference between these 2 age groups at the MP joint ($P < .050$) and the PIP joint ($P < .010$). When comparing the patients by gender, there was no statistically significant difference between the final correction percentages for either joint.

To determine efficacy of NA, we evaluated several criteria. There was a successful correction to a residual contracture of 5° or less, after 1 procedure, in 98% of

TABLE 2. Final Correction Percentage, by Joint and Digit

	MP Joint	PIP Joint
Thumb	89	
Index	48	48
Middle	74	36
Ring	72	34
Little	72	26

MP joints and 67% of PIP joints. There was a recurrence of 20° or less over the original postprocedure corrected level in 80% of MP joints and 35% of PIP joints. An improvement of extension 50% or more of the initial contracture was maintained at final follow-up in 75% of MP joints and 33% of PIP joints.

Complications were rare, except for skin tears, which occurred in 3.4% (34) of digits. All tears healed with no intervention other than local wound care. There was a temporary neuropraxia in 1.2% (6) of patients and a presumed nerve laceration in 0.1% (1) (ulnar digital nerve of little finger). None of these patients had a secondary procedure performed. There were no known instances of arterial laceration, tendon rupture, pulley rupture, hematoma, infection, or complex regional pain syndrome, and no patient was hospitalized.

DISCUSSION

Few papers have been published evaluating the results of NA. There is no uniform definition of either recurrence or success, which makes it difficult to directly compare results (Table 3).

Several groups of surgeons and rheumatologists have reported the French experience with NA. In 1993, Badois et al¹² published, in French, the results of NA. There were no major complications, although there was a skin break in 16%, digital dysesthesia in 2%, and infection in 2%. Bleton et al¹³ (1997) documented the results of a prospective study of NA. All complications were minor, including skin tear in 4%, temporary paresthesia in 2%, and superficial infection in 1%. In 1997, Lermusiaux et al¹⁴ related the results of a large number of NA procedures. An improvement of over 70% was observed in 81% of hands. The complication rate was 0.05% for both tendon and digital nerve injuries. Foucher et al⁹ (2003) reported a 79% gain in extension for the MP joint and 65% for the PIP joint. There was 1 digital nerve injury.

In 2006, van Reissen and Werker,¹⁰ from The Netherlands, described a postprocedure improvement of 77%. Their definition of recurrence was an increase in

TABLE 3. Fasciotomy Recurrence Rates

Publication	N	Recurrence Rate	Mean Follow-up Time
Badois et al ¹²	90 patients	50%	5 y
Bleton et al ¹³	110 digits	35%	6 mo
Lermusiaux et al ¹⁴	799 patients	Not reported	2 y
Foucher et al ⁹	100 patients	58%	3 y
van Rijssen and Werker ¹⁰	55 digits	65%	33 mo
Pess et al (current study)	1,013 digits	48%	3 y

TABLE 4. Fasciotomy Recurrence Rates

Publication	N	Recurrence Rate	Mean Follow-up Time
Ullah et al ¹⁵	79	12%	3 y
Gelberman et al ¹⁶	24	13%	18 mo
Dias and Braybrooke ¹⁷	1,177	15%	27 mo
Citron and Nunez ¹⁸	79	26%	2 y
Hueston ¹⁹	224	28%	5 y
Cools and Verstreken ²⁰	28	34%	2.5 y
Adam and Loyes ²¹	85	34%	41 mo
Foucher et al ²²	107	41%	5.6 y
Nieminen and Lehto ²³	70	43%	47 mo
Tonkin et al ²⁴	128	47%	38 mo
Juriscic et al ²⁵	93	73%	7 y

the passive extension deficit of greater than 30°. Two patients had diminished sensibility (3%). There were no flexor tendon injuries.

Published reports on the results of fasciotomy also use a variety of definitions of both correction of contracture and recurrence.^{15–25} This makes it difficult to compare the results of NA with fasciotomy. Recurrence rates of fasciotomy range from 12% to 73%^{12–25} (Table 4).

The results of our study reveal the success rate, efficacy, and safety to be similar to previously published reports on the use of NA. The recurrence rates are higher than for fasciotomy. Complications were rare and minimal. We attributed the low complication rate to the use of a short 25-gauge needle and accurate placement of the needle within the cord in an awake or responsive patient. Patients were constantly encouraged

to immediately inform the surgeon if they felt any electric shocks.

Needle aponeurotomy should be one of the treatment options for Dupuytren contracture. We recommend starting with simple MP joint contractures. Patience is necessary and the temptation to use a needle larger than 25 gauge should be resisted. It is critical to ask patients if they feel an electric shock each time the needle is inserted in a portal. Pinching the cord between the fingertips allows precise placement of the needle. The needle should be replaced frequently to maintain a sharp cutting edge. Placing gentle tension on the cord makes it easier and safer to release the cord. The flexor tendons should be relaxed. Sometimes it is safer to release the cord by massaging the area of the release rather than aggressively extending the finger. The massage technique also works well for natatory cords and cords in the first web. When a lateral cord is completely released but the PIP joint does not fully extend, there may be a nonpalpable central extension of the cord. An additional release centrally, just proximal to the PIP flexion crease, often completes the correction.

Almost all contractures can be improved when a cord is palpable. Needle aponeurotomy will not correct contractures resulting from postsurgical scarring and inadequate skin or capsular contractures of the PIP joint. It may be difficult or impossible to correct a PIP joint contracture when there is a large nodule or cord between the proximal digital flexion crease and PIP flexion crease. Patients should be educated preoperatively about the possibility of skin tear and temporary neuropraxia, and about the need to avoid heavy grasping activities for 2 weeks.

There were limitations to this study. We performed follow-up at a variety of intervals. The senior author did not make all measurements. Initial correction achieved postprocedure was not compared with correction maintained at the first follow-up visit.

Previous reports have used various criteria for correction and recurrence and have reported on variable lengths of follow-up. Our study clearly defines both correction and recurrence and provides a minimum 3-year follow-up. Standardizing the reporting of results will allow meaningful comparison of different treatments for Dupuytren contracture in the future.

The statistically significantly higher recurrence rate for PIP joints and in younger patients is troubling, and additional studies are necessary. At this time, we are evaluating whether repeating multiple NA procedures on the same joint produces improves long-term results.

REFERENCES

1. Cline H. Notes on pathology. London: St. Thomas Manuscript Collection, 1777:185.
2. Cooper A. A treatise on dislocations and on fractures of the joints. 2nd ed. London: Longman, Hurst, 1823:570–576.
3. Adams W. On contractions of the fingers (Dupuytren and congenital contractions) and hammer-toe. London: Churchill, 1892.
4. Goyrand G. Nouvelles recherches sur la retraction permanente des doigts. *Gazette Medicale Paris* 1883;3:481–486.
5. Fergusson W. A system of practical surgery. London: Churchill, 1842.
6. Luck JV. Dupuytren's contracture. A new concept of the pathogenesis correlated with surgical management. *J Bone Joint Surg* 1959; 41A:635–664.
7. Lermusiaux JL, Debeyre N. Le traitement medical de la maladie de Dupuytren. *Rhumatologique*. Paris: Expansion Scientifique, 1979: 338–343.
8. Badois FJ, Lermusiaux C, Masse C, Kuntz D. Nonsurgical treatment of Dupuytren disease using needle fasciotomy. *Rev Rhem Engl Ed* 1993;60:692–697.
9. Foucher G, Medina J, Navarro R. Percutaneous needle aponeurotomy: complications and results. *J Hand Surg* 2003;28B:427–431.
10. van Rijssen AL, Werker PN. Percutaneous needle fasciotomy in Dupuytren disease. *J Hand Surg* 2006;31B:498–501.
11. Eaton C. Percutaneous fasciotomy for Dupuytren contracture. *J Hand Surg* 2011;36A:910–915.
12. Badois FJ, Lermusiaux JL, Massé C, Kuntz D. Traitement non chirurgical de la maladie de Dupuytren par aponevrotomie a l'aiguille. *Rev Rhum Ed Fr* 1993;60:808–813.
13. Bleton R, Marcireau D, Almot J-Y. Treatment of Dupuytren disease by percutaneous needle fasciotomy. In Saffer P, Amadio PC, Foucher G, eds. *Current practice in hand surgery*. London: Martin Dunitz, 1997:187–193.
14. Lermusiaux JL, Lellouche H, Badois F, Kuntz D. How should Dupuytren contracture be managed in 1997? *Rev Rhum Engl Ed* 1997;64:775–776.
15. Ullah AS, Dias JJ, Bhowal B. Does a "firebreak" full-thickness skin graft prevent recurrence after surgery for Dupuytren contracture? A prospective, randomised trial. *J Bone Joint Surg* 2009;91B:374–378.
16. Gelberman RH, Amiel D, Rudolph RM, Vance RM. Dupuytren contracture. An electron microscopic, biochemical, and clinical correlative study. *J Bone Joint Surg* 1980;62A:425–432.
17. Dias JJ, Braybrooke J. Dupuytren contracture: an audit of the outcomes of surgery. *J Hand Surg* 2006;31B:514–521.
18. Citron ND, Nunez V. Recurrence after surgery for Dupuytren disease: a randomized trial of two skin incisions. *J Hand Surg* 2005; 30B:563–566.
19. Hueston JT. Recurrent Dupuytren contracture. *Plast Reconstr Surg* 1963;31:66–69.
20. Cools H, Verstreken J. The open palm technique in the treatment of Dupuytren disease. *Acta Orthop Belg* 1994;60:413–420.
21. Adam RF, Loynes RD. Prognosis in Dupuytren disease. *J Hand Surg* 1992;17A:312–317.
22. Foucher G, Cornil C, Lenoble E. Open palm technique for Dupuytren disease. A five-year follow-up. *Ann Chir Main Memb Super* 1992;11:362–366.
23. Nieminen S, Lehto M. Resection of the palmaris longus tendon in surgery for Dupuytren contracture. *Ann Chir Gynaecol* 1986;75: 164–167.
24. Tonkin MA, Burke FD, Varian JP. Dupuytren contracture: a comparative study of fasciotomy and dermofasciotomy in one hundred patients. *J Hand Surg* 1984;9B:156–162.
25. Jurisic D, Kovic I, Lulic I, Stanec Z, Kapovic M, Urvic M. Dupuytren disease characteristics in Primorsko-goranska County, Croatia. *Coll Antropol* 2008;32:1209–1213.